



Intraoral Lipoma- A Rare Case Report

Shalini Subramanyam*¹, Peeyush Shivhare²

¹Oral and Maxillofacial Pathologist & General Dental Surgeon, India

²Department of Oral Medicine and Oral Radiology, Nobel Medical College Teaching Hospital, Nepal

***Corresponding author:** Shalini Subramanyam, Oral and Maxillofacial Pathologist & General Dental Surgeon, India.

Received Date: March 17, 2021; **Published Date:** April 04, 2021;

© All rights reserved by Shalini Subramanyam., et al.

Abstract

Lipoma are most common benign mesenchymal neoplasm composed of mature Adipocytes. It account for 15–20% of cases occurring in head and neck region, while only 1-4% cases seen intraorally. Clinically, it presents as slow growing well circumscribed submucosal nodular swellings, which is painless with either yellow color or that of normal mucosa. The diagnosis is usually confirmed based on microscopic features, which consist of mature Adipocytes with uniform nuclei and scanty connective tissue. Intraoral Lipoma is exceedingly rare, thus we are reporting a case of intraoral Lipoma.

KeyWords: Simple Lipoma, Fibrolipoma, Spindle Cell Lipoma

Introduction

Lipomas are most common benign mesenchymal neoplasms composed of mature Adipocytes [1]. It accounts for 15–20% of cases occurring in head and neck region, while only 1-4% cases seen intraorally [1,2]. Generally, it affects the region of the trunk, shoulders, neck and axilla while intraoral site are buccal mucosa, followed by tongue, floor of mouth, lips, and gingiva. They particularly occur in the areas of fat accumulation thus buccal mucosa is more common site of occurrence [3]. Few palatal cases also have been reported in literature [4]. Clinically it presents as slow growing well circumscribed submucosal nodular swellings, which is painless with either yellow colour or that of normal mucosa. 1-5 Lipomas of the oral

and maxillofacial region have shown equal predilection for gender and affects patients mostly above 40 years of age with peak occurrence in the fifth or sixth decades of life.

Many factors such as mechanical, endocrine, and inflammatory influences have been proposed its etiology and pathogenesis. 1,2 Histopathologically, lipomas are composed of mature fat cells, can be classified as simple lipoma, fibrolipoma, spindle cell lipoma, intramuscular or infiltrating lipoma, angiolipoma, pleomorphic lipoma, myxoid lipoma, and atypical lipoma. The most common histopathological type of lipoma is a simple lipoma 1-5.

Case report

A 41-year-old female patient reported with the chief complaint of swelling on the inner part of right cheek near corner of mouth region since 1 year. Swelling was gradually increasing in size as noticed by the patient. The patient also complained of discomfort in chewing the food as that growth interferes while biting. The patient did not have any relevant medical history and family history. Intraoral examination showed dome shaped growth of about 2.5x1.5cm on the retrocommisure area in relation to 43-45 region [Figure 1]. It was movable, pedunculated, soft in consistency and nontender. It was pale pink and covered with normal mucosa without ulceration or inflammation. Under aseptic conditions, excisional biopsy was done under local anaesthesia using laser 980nm, 2 watt (indilase). 3.0 silk sutures were used. Tissue was excised and stored in 10% formalin for further histopathological investigations [Figure 2].

On gross examination, these tumours were soft, well circumscribed, and non-infiltrating. Microscopically, these tissues revealed sheets of mature adipocytes containing clear cytoplasm and eccentric nucleus, with no evidence of cellular atypia or metaplasia. The tumour cells were arranged in lobules with intervening fibrovascular connective tissue septa [Figure 3]. Based on the histopathological features, the diagnosis of lipoma was made.

Discussion

The first description of oral lipomas was given by Roux in 1848 as "yellow epulis."⁴The etiology is still not clear, but a role of various factors has been reported such as trauma, chronic irritation,

endocrine, and inflammation.

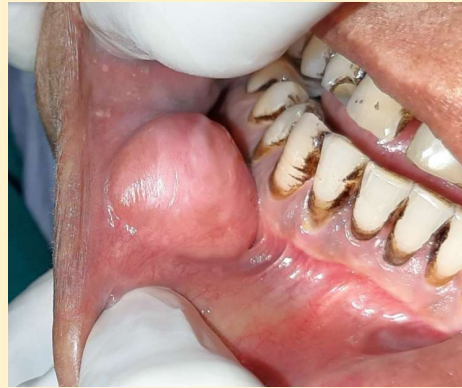

Figure 1: Dome shaped soft tissue swelling on retrocommisure area in relation to 43-45 region.

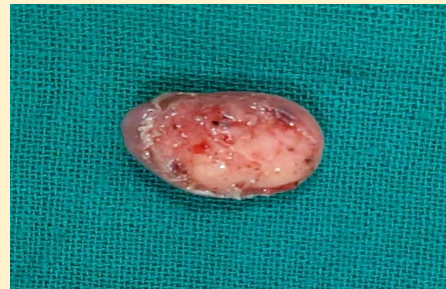

Figure 2: Gross examination of excised tissue.

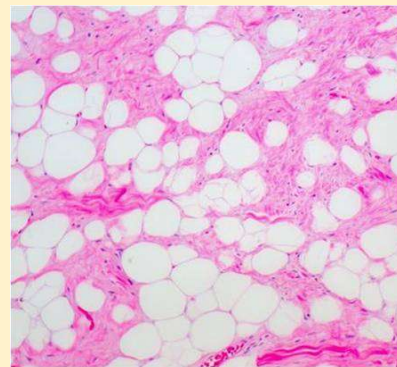


Figure 3: Microscopically, sectioned tissues appeared as sheets of mature adipocytes containing clear cytoplasm and eccentric nucleus, with no evidence of cellular atypia or metaplasia.

The two theories had been proposed are hypertrophy theory and metaplasia theory. "Hypertrophy theory" believed that these tumours occur in oral cavity due to obesity and inadvertent growth of adipose tissue. while "metaplasia theory" states that aberrant differentiation of mesenchymal cells into lipoblasts leads to the development of lipoma.

Intraoral Lipomas are rare and the pattern of location of this depends on the quantity of fat deposits in the oral cavity thus lipoma most commonly seen in buccal mucosa and rare in palate. The palate has very little fatty tissue thus incidence of a lesion here is quite low.

Intraoral lipomas are slow growing and usually asymptomatic until they grow to large size and may interfere with speaking and mastication. Clinically these are well defined, smooth surfaced tumour, soft to firm in consistency based on the extent of fibrous capsule. The size of tumour depends on the location but rarely exceeds 25 mm in diameter, but few cases of size extending 5cm have reported.

Clinical diagnosis of superficial lesion is not intricate due to yellow colour of the lesion and soft consistency on palpation. Deep seated lesions should be differentiated (based on clinical sites) from fibroma, mucocele, minor salivary gland tumors, leiomyoma, rhabdomyoma, lymphangioma, neuroma, neurofibromas, granular cell tumor, oral dermoid and epidermoid cysts, oral lymphoepithelial cyst, benign mesenchymal neoplasm, ranula, ectopic thyroid tissue, and lymphoma.

While histologically, the entities such as fibroma, leiomyoma, minor salivary gland tumors, papilloma, mucocele and epidermoid cyst should be differentiated.

The term "lipomatosis" is used to describe multiple lipomas, which are predominantly in upper half of the body and are three times more in male than females. The multiple lipomas can be associated with Cowden's syndrome, Proteus syndrome, Bannayan-Zonana syndrome and Frohlich syndrome.

The diagnosis is usually confirmed based on microscopic features, which consist of mature Adipocytes with uniform nuclei and scanty connective tissue. The cytological examination of the tissue is also significant which is obtained by fine needle aspiration. Radiological examination usually not required but rarely Ultrasound, CT scan or MRI are advised for a large infiltrating cases.

Treatment for intraoral lipoma is complete surgical excision. No recurrence has been described after local excision. The diode laser can be used as a modality for oral soft-tissue surgery. Excision with laser would reduce bleeding and also lower swelling and scarring of the surgical site, comparing to the simple surgeries. 10 Medical management of lipomas, which is now common, includes steroid injections that result in local fat atrophy, thus, shrinking the tumor size. They are best done on lipomas that are <1" in diameter.

References

1. Fregnani ER, Pires FR, Falzoni R, Lopes MA, Vargas PA (2003) Lipomas of the oral cavity: Clinical findings, histological classification and proliferative activity of 46 cases. *Int J Oral Maxillofac Surg* 32: 49-53.
2. Furlong MA, Fanburg SJC, Childers EL (2004) Lipoma of the oral and maxillofacial region: Site and subclassification of 125 cases. *Oral Surg Oral Med Oral Pathol Oral Radiol Endod* 98: 441-450.
3. Kumar LK, Kurien NM, Raghavan VB, Menon PV, Khalam SA (2014) Intraoral lipoma: A case report. *Case Rep Med* 2014: 480130.
4. Bakshi SS, Priya M, Coumare VN, Vijayasundaram S, Karanam LA (2015) Common tumor in an uncommon location: Lipoma of the palate. *M Ann Maxillofac Surg* 5: 237-239.
5. Adoga AA, Nimkur TL, Manasseh AN, Echejoh GO (2008) Buccal soft tissue lipoma in an adult Nigerian: A case report and literature review. *J Med Case Rep* 2: 382.
6. Manor E, Sion-Vardy N, Joshua BZ, Bodner L (2011) Oral lipoma: Analysis of 58 new cases and review of the literature. *Ann Diagn Pathol* 15: 257-261.
7. Sharma G, Jain K, Nagpal A, Baiju CS (2016) A rare presentation of lipoma on mandibular mucogingival junction. *J Indian Soc Periodontol* 20: 199-202.
8. Park BG, Choi DJ, Park JW, Kim JS (2015) Oral cavity lipoma: a case report. *J Korean Assoc Oral Maxillofac Surg* 41: 213-216
9. Weiss SW, Goldblum JR (2001) Benign lipomatous tumors. In Enzinger FW, Weiss SW, editors. *Soft Tissue Tumors. 4th ed. St.Louis: Mosby.*
10. Wagle SV, Agrawal AA, Sankhe R, Bardoliwala D (2019) Surgical excision of intraoral lipoma on buccal mucosa. *J Oral Res Rev* 11: 85-88.

Copyright: © 2021 Shalini Subramanyam., *et al.*

This is an open-access article distributed under the terms of the Creative Commons Attribution License, which permits unrestricted use, distribution, and reproduction in any medium, provided the original author and source are credited.